

# Arthroscopic Meniscal Repair Using the Outside-In Technique

## *Indications, Technique, and Results*

Scott A. Rodeo, M.D. and Aruna M. Seneviratne, M.D.

---

**Summary:** The outside-in technique has been demonstrated to be effective for repair of most meniscal tears. Peroneal nerve injury is easily avoided during lateral meniscal repair using this technique because the starting point for needle entry is controlled. There are several advantages of this technique: sutures can be placed without the need for a rigid cannula, precise suture placement is possible because only small needles are used, visualization is facilitated because there are no instruments between the meniscus tear and the arthroscopic view, and the repair can be performed with small incisions with minimal dissection. This technique can be adapted for use of either permanent or absorbable suture, and is useful for suturing a meniscal replacement device (such as a meniscus allograft or collagen meniscus implant) or for securing materials such as a fibrin clot or a carrier containing growth factors to a repair site. **Key Words:** Meniscal repair—Meniscus—Arthroscopy—Fibrin clot.

---

The well established importance of the meniscus in load transmission across the knee joint has led to the development of techniques to repair meniscal tears. Advances in our understanding of basic meniscus biology and meniscal healing have improved the ability to select appropriate tears for repair and to design methods to enhance meniscal healing. Several different techniques, each with particular advantages and disadvantages, are used for meniscus repair. This article reviews the technique, indications, and results of meniscus repair using the outside-in method.

### INDICATIONS

The outside-in technique of arthroscopic meniscal repair was developed by Warren<sup>1</sup> as a method to decrease the risk of injury to the peroneal nerve during arthroscopic lateral meniscal repair. Peroneal nerve injury is easily avoided during lateral meniscal repair because the starting point for nee-

dle entry is controlled. The outside-in technique can be used for repair of most meniscal tears. Tears in the anterior portion of the meniscus are easily accessed with this technique. In far posterior tears of the meniscus, it may be difficult to start far enough posteriorly, thus resulting in oblique suture orientation across the tear. In this setting, the inside-out technique with a posterior incision may be preferable.<sup>2</sup>

The outside-in method can be used for suturing a meniscal replacement (such as an allograft or synthetic device) to the capsule (Fig. 1). Implantation of a collagen meniscus implant, which is currently in clinical trials as a segmental meniscal replacement, may be facilitated using the outside-in technique. Implantation of this device requires use of a grasping instrument introduced into the joint through an anterior portal to hold the implant, and thus suturing may be easier if the needles are placed from outside-in. The outside-in method is also useful for securing materials such as a fibrin clot or a carrier containing growth factors to a repair site. A suture can be placed across the tear, and then the implant or fibrin clot can be attached to the suture and brought into the tear site. Secure repair of meniscal tears or a meniscal replacement may often require a combination of methods, and thus the surgeon should be comfortable with several methods.

---

From the Sports Medicine and Shoulder Service, The Hospital for Special Surgery, New York, New York.

Address correspondence and reprint requests to: Scott A. Rodeo, M.D., The Hospital for Special Surgery, 535 East 70th Street, New York, NY 10021.

Email: rodeos@hss.edu

# Microscopic Examination of the L. Chrysalis

John A. Gahan, M.D., University of Michigan

The chrysalis of the silkworm is a highly specialized structure, adapted for the protection and development of the pupa. It is composed of a series of layers, each with a specific function. The outermost layer is the cuticle, which is composed of chitin and protein. This layer is responsible for the structural integrity and protection of the pupa. Beneath the cuticle is the epidermis, which is the source of the silk fibers. The epidermis is composed of a single layer of cells, each of which secretes a protein called fibroin. The fibroin is then spun into a continuous filament of silk. The silk fibers are then woven into a cocoon, which is the protective covering of the pupa. The cocoon is composed of a series of layers, each of which is made of silk fibers. The cocoon is a highly complex structure, and its formation is a highly coordinated process. The pupa is able to move within the cocoon, and it is able to breathe through a series of spiracles. The pupa is able to survive for several weeks within the cocoon, and it is able to emerge as an adult moth. The chrysalis is a highly specialized structure, and its study is of great importance to the study of insect development.

The chrysalis of the silkworm is a highly specialized structure, adapted for the protection and development of the pupa. It is composed of a series of layers, each with a specific function. The outermost layer is the cuticle, which is composed of chitin and protein. This layer is responsible for the structural integrity and protection of the pupa. Beneath the cuticle is the epidermis, which is the source of the silk fibers. The epidermis is composed of a single layer of cells, each of which secretes a protein called fibroin. The fibroin is then spun into a continuous filament of silk. The silk fibers are then woven into a cocoon, which is the protective covering of the pupa. The cocoon is composed of a series of layers, each of which is made of silk fibers. The cocoon is a highly complex structure, and its formation is a highly coordinated process. The pupa is able to move within the cocoon, and it is able to breathe through a series of spiracles. The pupa is able to survive for several weeks within the cocoon, and it is able to emerge as an adult moth. The chrysalis is a highly specialized structure, and its study is of great importance to the study of insect development.

The chrysalis of the silkworm is a highly specialized structure, adapted for the protection and development of the pupa. It is composed of a series of layers, each with a specific function. The outermost layer is the cuticle, which is composed of chitin and protein. This layer is responsible for the structural integrity and protection of the pupa. Beneath the cuticle is the epidermis, which is the source of the silk fibers. The epidermis is composed of a single layer of cells, each of which secretes a protein called fibroin. The fibroin is then spun into a continuous filament of silk. The silk fibers are then woven into a cocoon, which is the protective covering of the pupa. The cocoon is composed of a series of layers, each of which is made of silk fibers. The cocoon is a highly complex structure, and its formation is a highly coordinated process. The pupa is able to move within the cocoon, and it is able to breathe through a series of spiracles. The pupa is able to survive for several weeks within the cocoon, and it is able to emerge as an adult moth. The chrysalis is a highly specialized structure, and its study is of great importance to the study of insect development.

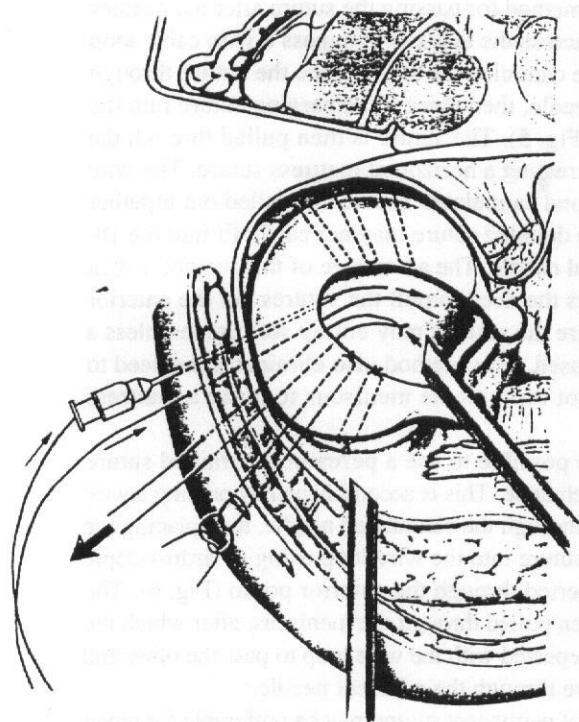


FIG. 1. The outside-in technique can be used for suturing a meniscal allograft to the capsule. (Reprinted with permission from Rodeo SA, Warren RF. *Clin Sports Med* 1996;15(3):469-481.)

#### ADVANTAGES OF THE OUTSIDE-IN METHOD

A significant advantage of the outside-in method is that sutures can be placed without the need for a rigid cannula for suture placement, as is used by many inside-out techniques. Although there is a risk of causing minor damage to the articular surfaces when introducing needles from outside the joint, there is also risk of scraping the articular surfaces when using a rigid cannula in the inside-out technique. The outside-in technique also allows precise suture placement in areas of limited access because only small needles are used, instead of the larger cannulas or needle holder used in the inside-out technique. This can facilitate vertical suture placement. Except in very tight medial compartments, excellent visualization is possible because there are no instruments between the meniscus tear and the arthroscopic view. Finally, the repair can be performed with smaller incisions with less dissection than used with the inside-out technique.

#### TECHNIQUE

The outside-in method requires only 18-gauge spinal needles, an arthroscopic grasper, and suture material.<sup>3</sup> Special instruments are also available, such as a wire cable loop for suture retrieval. The knee is placed into approxi-

mately 10 degrees of flexion for medial meniscus repair and 90 degrees of flexion for lateral meniscal repair to avoid peroneal nerve injury. While viewing the meniscus arthroscopically, the surgeon places the needle across the tear site from the outside. The starting point is located by palpation and by using topographic landmarks. Transillumination may be used to identify small cutaneous nerves and veins. The needle passes across the tear in the meniscus and penetrates the inner segment of the meniscus. The needle then enters the joint on either the superior (femoral) or inferior (tibial) surface of the inner segment of the meniscus (Fig. 2). A small skin incision is made and the subcutaneous tissue is spread down to the capsule. It is important to identify and protect the saphenous nerve and vein on the medial side.

A second needle is then passed, emerging from the meniscus adjacent to the first needle to achieve proper suture orientation. The second needle can be placed to create either a vertical or horizontal mattress suture across the tear. It is thought that a vertical suture orientation more effectively captures the circumferentially oriented collagen fibers of the meniscus. Suture (#0-polydioxanone [PDS]; Ethicon, Somerville, NJ) is next passed into each needle, grasped inside the joint, and pulled out the anterior portal (Fig. 3). PDS suture is used because it is rigid enough to push through the needles.

There are two ways to complete the repair. A knot may be made in the end of the suture with three or four throws in a standard square-knot configuration. The knot is then pulled back into the joint so that the knot lies against the meniscus and maintains the tear in a reduced position. Adjacent sutures are then tied together subcutaneously over the capsule. An alternative way to complete the repair is

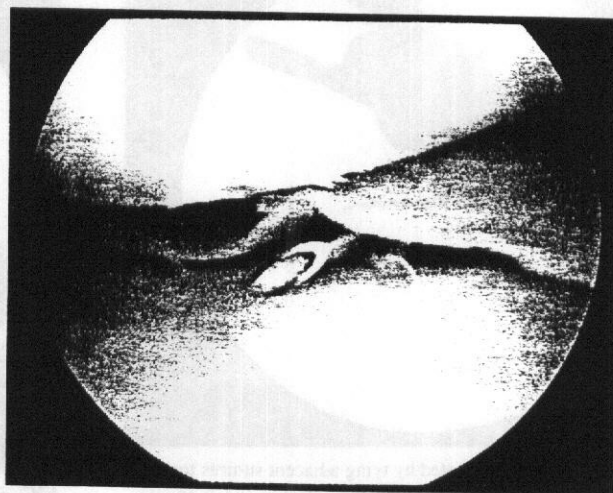


FIG. 2. The spinal needle is placed across the meniscus tear from the outside, going across the tear and entering the joint on the tibial or femoral side of the inner segment of the tear.

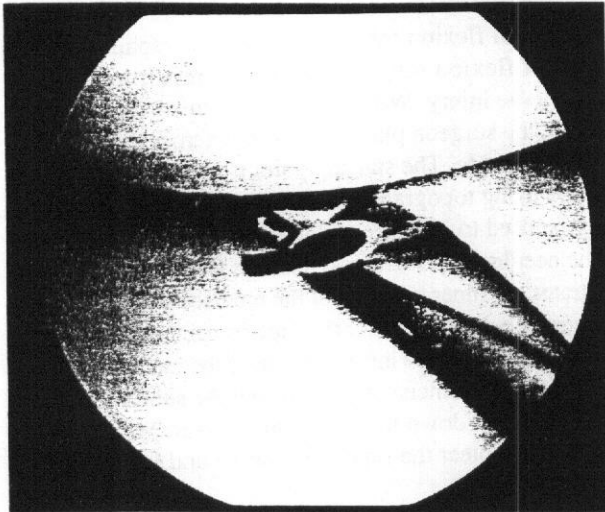


FIG. 3. #0-Polydioxanone (PDS) sutures are placed through the needle from the outside.

to tie adjacent sutures together outside the anterior portal, using a standard square knot. The knot is then pulled through the meniscus and adjacent sutures are tied together subcutaneously over the capsule. This technique allows creation of a mattress suture. This may be facilitated by placing a smaller "dilator knot" in front of the knot holding the two ends together, then pulling the sutures so that this dilator knot passes through meniscus before the larger knot (Fig. 4). The dilator knot is a square knot made with only two throws.



FIG. 4. A mattress suture is created by tying adjacent sutures together outside the knee and then pulling the knot through the meniscus. (Reprinted with permission from Rodeo SA, Warren RF. *Clin Sports Med* 1996;15(3):469-481.)

Another method for passing the suture after the needles are placed across the tear site is to pass a wire cable loop through one cannulated needle, place the suture through the other needle, then place the emerging suture into the wire loop (Fig. 5). The suture is then pulled through the meniscus, creating a horizontal mattress suture. The wire cable loop and cannulated needle are pulled out together because the doubled suture may not easily fit into the 18-gauge spinal needle. The advantage of this method is that it eliminates the need to pull the sutures out the anterior portal, where the sutures may entrap soft tissue unless a cannula is used. This method also eliminates the need to pull the knot through the meniscus to make a mattress stitch.

It is also possible to use a permanent, braided suture with this technique. This is accomplished by passing a wire cable loop through the cannulated needle, then placing the end of the suture into the wire loop using an arthroscopic grasper inserted through the anterior portal (Fig. 6). The suture is then pulled through the meniscus, after which the process is repeated with the wire loop to pass the other end of the suture through the adjacent needle.<sup>4</sup>

The use of permanent suture may be preferable for repair of tears with poor healing potential, such as those in older patients, chronic tears, or tears with marginal vascularity. The choice of permanent versus absorbable suture for meniscal repair has been an area of debate. Barrett et al.<sup>5</sup> demonstrated that menisci repaired with permanent sutures had a lower incidence of clinical symptoms and a much lower failure rate. This is thought to be because permanent sutures allow for a longer and more stable fixation, permitting more complete maturation and remodeling of the healing meniscus.

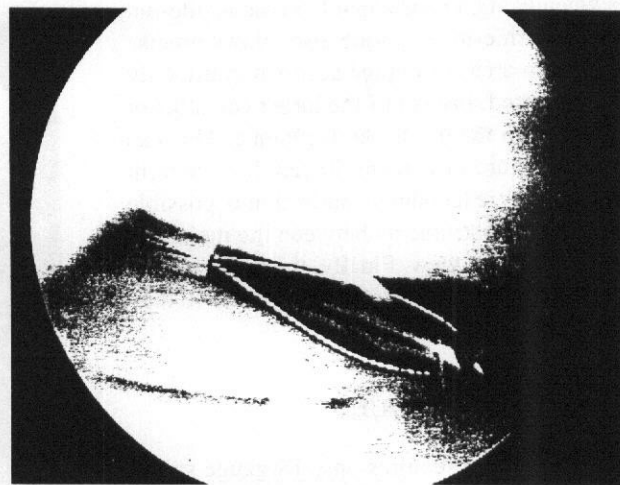


FIG. 5. A wire cable loop is passed through one cannulated needle and a suture is placed through an adjacent needle. The emerging suture is then placed into the wire loop and pulled to the outside.

cus. PDS suture has the longest resorption time and is rigid enough to push easily through the spinal needle.

### SPECIAL TECHNICAL CONSIDERATIONS

Careful attention to technique aids in the successful use of the outside-in method. Several other tips also help to avoid problems and simplify the procedure. Needle placement across the meniscus may be made easier by using a probe or small loop curette to provide counterpressure on the meniscus during needle placement. It is helpful to place both needles across the tear site before passing the sutures to avoid the second needle cutting a previously placed suture. When pulling sutures out through the anterior portal, it is recommended to use a cannula in the anterior portal to avoid entrapment of soft tissue between the sutures. A 7-mm diameter arthroscopic cannula (Linvatec, Largo, FL) allows passage of most standard arthroscopic grasping instruments. After one set of sutures has been placed, these sutures should be tied and pulled back into the knee before the next set of sutures is placed. This avoids tangling of adjacent sets of sutures inside the knee.

Needle placement must remain anterior to the biceps tendon on the lateral side to avoid injury to the peroneal nerve. Curved needles (Acufex, Mansfield, MA) may be used for posterior tears to decrease the need for a posterior starting point and thus decrease the risk of neurovascular injury. Valgus or varus load can be applied when placing sutures on the medial or lateral meniscus, respectively, to open the compartment and make needle placement easier. This also approximates the capsule to the meniscus, thus aiding in accurate meniscal repair. Accurate needle placement may require access to the posterior joint line. For lateral repairs, the knee may be placed into a "figure-of-four" position (flexion of the knee and external rotation of the hip). In this position, the lateral side of the knee can project over the edge of the table, providing access to the posterior joint line. For medial meniscal repairs, it is helpful to drop the foot of the table to allow access to the posterior joint line.

If the needle points down toward the tibial surface as it enters the joint, the suture will be difficult to pass into the joint because the suture will hit the tibial surface. This problem can be solved by using a probe passed through the anterior working portal to hold up the tip of the needle and thus allow easier passage of suture into the joint. The needle can also be manipulated from the outside to place the tip in a position that allows easy passage of suture into the knee.

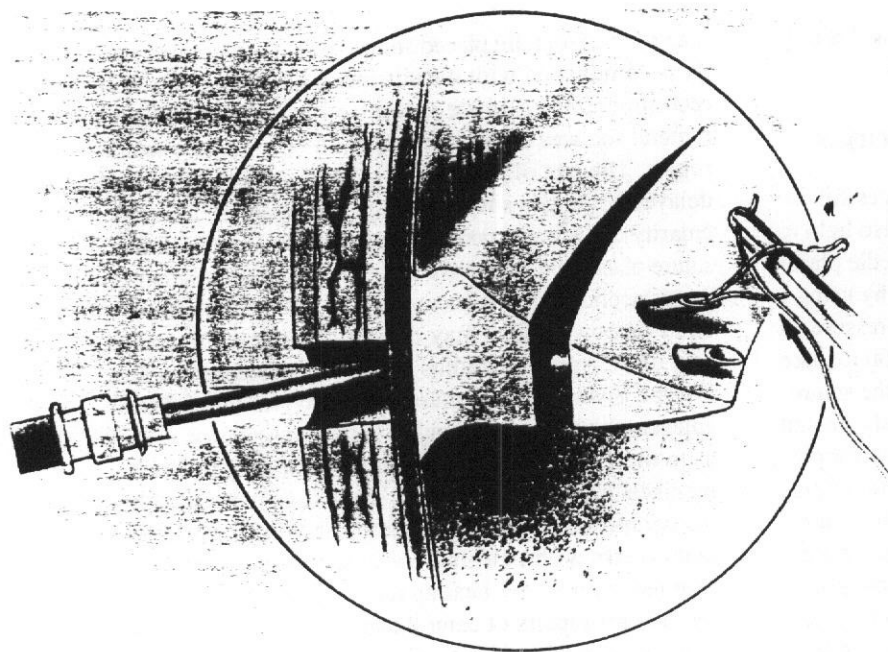
Vertical suture orientation may be preferable because it captures more circumferential collagen bundles. The failure strength of vertical suture has been reported to be higher

than for horizontally placed suture.<sup>6</sup> This orientation is easily accomplished with the outside-in technique. It is also recommended to place sutures on both the tibial and femoral surfaces of the meniscus to allow for a more secure repair. The use of permanent suture is recommended if delayed healing is suspected (e.g., older patient, poor vascularity). It is important to abrade the tear surfaces before suture placement to remove any synovial covering or amorphous acellular debris accumulation, and to stimulate vascular ingrowth. This may be accomplished with a rasp, bur, or 3.5-mm full-radius resector. Consideration may also be given to abrasion of the synovium immediately adjacent to the tear to stimulate further vascularity, as well as to the use of fibrin clot to augment healing in isolated meniscal repairs. Ritchie et al.<sup>7</sup> have shown that abrading the parameniscal synovium for repair of centrally located tears (tears with marginal vascularity) in a goat model resulted in an 87.5% healing rate versus only a 17% healing rate for repairs of central tears augmented with fibrin clot. We consider the use of fibrin clot for most isolated meniscal repairs in addition to parameniscal synovial abrasion, especially in those tears with marginal vascularity. Fibrin clot is not necessary with concomitant anterior cruciate ligament (ACL) reconstruction because there is already a hemarthrosis from the ACL reconstruction. In the setting of concomitant ACL reconstruction, the meniscal repair sutures should be placed but not tied until the ligament graft is secured.

The fibrin clot is prepared from 50 to 60 ml of the patient's blood, obtained by venipuncture.<sup>8</sup> The blood is placed in a sterile glass container and stirred with a glass rod to promote coagulation. The clot forms within 3 to 5 minutes, is 1 to 2 cm in diameter, and has a firm consistency. The clot is then rinsed with sterile saline and gently blotted between gauze sponges to remove serum and red blood cells. The clot can be inserted by tying it to a previously placed suture that has been brought out the anterior portal through a large cannula. This suture with the attached fibrin clot is then pulled back into the knee. The clot may also be placed into a plastic tube with a pusher and then inserted into the tear through the tube or injected through a syringe with a blunt needle. Most tears are filled by 1.5 to 2 ml of clot (Fig. 7). The clot may be secured with 0-PDS suture if needed.

### COMPLICATIONS

With careful attention to surgical technique and local anatomy, complications are rare. Saphenous nerve injury can occur during needle passage on the medial side or if the sutures are inadvertently tied around the nerve or its branches. Careful dissection combined with transillumi-



**FIG. 6.** A braided permanent suture can be placed into the wire cable loop through the anterior portal. (Reprinted with permission from Johnson L. Meniscus repair: The outside-in technique. In: Jackson DW, ed. *Master Techniques in Orthopaedic Surgery: Reconstructive Knee Surgery*. New York: Raven Press; 1995:61.)

nation decreases this risk. Peroneal nerve injury is avoided by performing lateral meniscal repair with the knee in 90 degrees of flexion and starting needle placement anterior to the biceps tendon.

Superficial infection may occur if careful soft tissue coverage over the sutures is not achieved. A two-layered wound closure over the sutures is recommended. Local acidity during degradation of absorbable sutures may contribute to the risk of infection. Aggressive early treatment of an infection usually salvages the repair.

Limitation of extension may theoretically occur because of entrapment of the posterior capsule if the knee is in too much flexion while sutures are tied that pass through the posterior capsule, especially on the medial side. This is quite unlikely to occur because during arthroscopic repairs the sutures are usually placed with valgus load applied to the knee, and in this position the capsule is closely apposed to the meniscus. This complication is probably more likely with open meniscal repair because the sutures are placed with the knee in flexion, a position in which the posterior capsule is lax, and could be accorded into the sutures. The use of absorbable sutures decreases the risk of permanent entrapment of the posterior capsule. Failure of healing can occur as a result of poor tear selection for repair (e.g., inadequate vascularity, degenerative tissue), knee instability, inadequate suture stabilization of the tear, too-oblique suture orientation across the tear, failure of early protection of the repair, and repeat injury. Careful attention to patient selection, surgical technique, and postoperative rehabilitation minimizes failure.

## REHABILITATION

Postoperative rehabilitation after meniscus repair continues to be an area of controversy. However, several recent studies have begun to shed light on this aspect of meniscus repair. Some recent studies have evaluated the results of meniscal repair using an accelerated rehabilitation protocol.<sup>9,10</sup> These studies demonstrated good meniscal healing rates, and thus do not support the need for activity restrictions after meniscus repair. Barber<sup>9</sup> reported no difference in results when comparing an accelerated rehabilitation protocol with a restricted, standard rehabilitation protocol. An accelerated rehabilitation protocol was initially advocated by Shelbourne et al.,<sup>11</sup> who also report no difference in meniscus healing rates between an accelerated and a conventional rehabilitation program. Similar results have also been reported by Mariani et al.<sup>12</sup> Meniscal healing was evaluated by clinical symptoms only in most patients in these studies, as opposed to an objective evaluation using arthroscopy, arthrography, or magnetic resonance imaging (MRI).

Several recent studies have evaluated the effects of immobilization and weight bearing from a basic science standpoint. Klein et al.<sup>13</sup> initially showed that immobilization and non-weight bearing in a dog model resulted in significant atrophy of the soft tissues (lateral meniscus and ACL) as well as bone. These authors subsequently demonstrated that atrophy of ligaments and menisci can be prevented by active joint motion in a non-weight-bearing dog model.<sup>14</sup> Anderson et al.<sup>15</sup> used a sheep model to

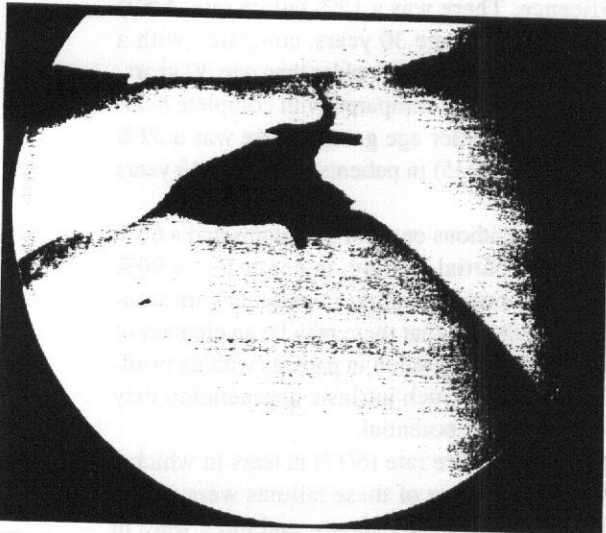


FIG. 7. A fibrin clot may be placed at the tear site to augment healing of tears with poor healing potential because of marginal vascularity, underlying meniscal degeneration, or older patient age.

demonstrate that the tensile properties of the meniscus were not significantly affected if even only limited joint motion was allowed. More recently, Dowdy et al.<sup>16</sup> have shown that prolonged immobilization leads to a decrease in collagen content within the healing meniscus, thus suggesting that patients undergoing isolated meniscal repair either be immediately mobilized after surgery or immobilized for short periods only.

Our current rehabilitation protocol involves use of a hinged, double-upright brace for the first 6 weeks after surgery. Early range-of-motion exercise is begun immediately, including full extension. Flexion is limited to 70 degrees during the first 4 weeks to protect posterior horn repairs. Full weight bearing with the brace locked in full extension is allowed as tolerated. There does not appear to be any adverse effect on meniscal healing if ambulation is allowed in full extension. The brace hinge is adjusted to allow a range of motion from 0 to 40 degrees during ambulation beginning at 4 weeks. Weight bearing out of the brace is allowed at 6 weeks. Running is begun at 3 to 4 months, with return to full athletic participation by 5 months. We discourage squatting and hyperflexion for up to 6 months after meniscal repair.

In the setting of concomitant ACL reconstruction, our usual ACL rehabilitation protocol is used because this provides appropriate protection of the healing meniscus. Our typical ACL rehabilitation protocol includes immediate full weight bearing in extension in a hinged brace. Progression to full range of motion is allowed immediately as tolerated, with emphasis on early achievement of full extension. At 3 to 4 weeks, the brace is unlocked to allow

restoration of normal gait. Weight bearing out of the brace is allowed at 4 to 6 weeks. Closed kinetic chain strengthening exercises are begun in the second week and progressed. Sport-specific activities are initiated at 6 to 8 weeks for further development of strength and proprioception. Running is begun at 3 to 4 months, with return to full athletic participation by 5 months.

## RESULTS

There are very few reports of the results of meniscal repair using the outside-in technique. Morgan and Casscells<sup>17</sup> were the first to report the results of outside-in meniscal repair. They report a 98% clinical healing rate, with a 2.8% complication rate with an 18-month follow-up. Their evaluation was based on a physical examination and symptoms only. This series included only acute tears in the outer third of the meniscus. Mariani et al.<sup>12</sup> reported good clinical results in 17 of 22 (77%) patients undergoing outside-in repair of medial meniscal tears in conjunction with ACL reconstruction. These authors reported a 14% failure rate (3/22) using clinical criteria for meniscal re-tear. These authors reported that MRI demonstrated a gap larger than 1 mm at the repair site in those patients with clinical symptoms of meniscal re-tear.

We have used objective criteria to evaluate the outcome of outside-in meniscal repairs performed at our institution between 1984 and 1988.<sup>18</sup> Of 96 patients, 6 were lost to follow-up, leaving a study group of 90 patients. The minimal follow-up was 3 years, with an average follow-up of 46 months (range, 36 to 89 months). There were 74 male and 16 female patients. The average age was 25 years (range, 11 to 54 years). The interval from injury to repair averaged 11 months (range, 1 week to 11 years). Patients injured while participating in athletics comprised 87% (78/90) of the total, whereas 12 patients reported an insidious onset of symptoms.

The posterior horn of the meniscus was torn in 91% (82/90) of the group. The peripheral third of the meniscus was torn in 87% (78/90). There were 72 (80%) medial and 18 (20%) lateral repairs. An exogenous fibrin clot was used in 17 repairs in an attempt to augment healing.<sup>8</sup> Seven of the repairs in which the fibrin clot was used were located in the middle third of the meniscus ("red-white" region). All patients were evaluated with physical examination, radiographs, and objective evaluation of the meniscus with either computed tomographic arthrography, MRI, or arthroscopic inspection. Four patients refused objective testing but underwent physical examination. The use of these objective outcome measures allowed more anatomic evaluation of the success of the healing process and excluded asymptomatic residual tears from the success group. Com-

plete meniscal healing was determined by the absence of dye leaking into the tear site on arthrogram, whereas partial healing was noted by intrusion of dye into one surface of the tear but without dye penetration to the other side of the tear. Failure of healing was noted by persistent dye throughout the entire thickness of the tear. MRI criteria for full healing include presence of low or moderate signal intensity at the tear site with complete apposition of the tear edges. Partial healing was noted on MRI by persistent high signal intensity but normal meniscus morphology at the tear site, whereas failure of healing was noted by high signal and abnormal meniscal morphology at the tear site.

Overall, 78 of 90 patients (87%) had a successful outcome. Sixty-two of 90 patients (69%) were asymptomatic and had objective evidence for complete healing of the meniscus (group I); 16 of 90 patients (18%) were minimally symptomatic and had objective evidence for partial healing (group II); and 12 of 90 patients (13%) had failure of healing (group III). There was a significant difference in healing rate between patients with a stable knee and those with an unstabilized ACL-deficient knee ( $P < 0.05$ ). The failure rate was 38% (5/13) in unstable knees, 15% (5/33) in stable knees, and only 5% (2/38) in patients undergoing concomitant ACL reconstruction. (It is likely that the hemarthrosis that occurs during ACL reconstruction provides serum factors that aid meniscal healing.)

The failure rate was higher for repairs of the medial meniscus compared with repairs of the lateral meniscus. The failure rate was 15% (11/72) for medial meniscus repairs, compared with a 5% failure rate (1/18) for lateral meniscal repairs. Tears that involved the posterior horn of the medial meniscus had the highest failure rate, especially in the setting of ACL insufficiency. This is most likely because the medial meniscus serves as a significant restraint to anterior tibial translation in the ACL-deficient knee. It is thus likely that in the ACL-deficient knee the medial meniscus is exposed to higher shear stresses and thereby is susceptible to injury. It is also possible that the higher failure rate for posterior tears was caused by oblique suture orientation across the tear.<sup>2</sup> Repairs failed more commonly in the central, less vascular portion of the meniscus. There was a 4% failure rate (1/23) for tears at the meniscocapsular junction, compared with a 40% failure rate (4/10) for tears in the central third of the meniscus ( $P = 0.02$ ).

There were 52 chronic and 38 acute repairs (defined as repair performed within 1 month of injury). There was no significant difference in the healing rate between these groups. The failure rate was higher for patients older than 30 years of age, although the difference did not reach sta-

tistical significance. There was a 12% failure rate (6/52) in patients younger than age 30 years, compared with a 16% failure rate (6/38) in patients older than age 30 years. The rate of partial healing, compared with complete healing, was higher in the older age group. There was a 32% rate of partial healing (8/25) in patients older than 40 years of age.

Patients with an insidious onset of symptoms had a 66% rate of complete or partial healing, in contrast to a 90% rate of complete or partial healing in patients with traumatic onset. This suggests that there may be an element of underlying meniscal degeneration in patients with an insidious onset of symptoms. Such intrinsic degeneration may result in a lower healing potential.

There was a 36% failure rate (6/17) in tears in which a fibrin clot was used. Three of these failures were attributed to unrepaired ACL insufficiency, and three were in complex tears in the avascular zone of the meniscus. Because the fibrin clot was used in tears with an inherently higher failure rate, no conclusions can be made regarding the efficacy of fibrin clot insertion. A randomized, prospective study is required to assess the efficacy of fibrin clot use in meniscal repair.

The complication rate was 3% (3/90). There was one superficial infection, one case of thrombophlebitis, and one saphenous nerve entrapment. The patient with saphenous nerve entrapment underwent immediate exploration, at which time the nerve was found to be entrapped by the sutures. Our philosophy of treatment of this complication is if the patient has burning paresthesias in the distribution of the saphenous nerve immediately after surgery, and these symptoms are made worse by knee extension, then immediate exploration is recommended. If there is only numbness in the saphenous nerve distribution, our recommendation is for observation. Exploration is recommended if symptoms persisted after 6 to 12 weeks.

A recent study from our institution has demonstrated different regional healing rates with the outside-in technique.<sup>3</sup> In this study, complete healing occurred in 45%, partial healing in 32%, and no healing in 24%. There was a significantly lower healing rate for tears in the posterior horn of the medial meniscus, which was thought to be caused by the obliquity of the sutures in this region. It can be difficult to place the needles perpendicular to the tear in the far posterior zone of the meniscus, resulting in oblique suture placement. The coaptation force of the sutures may be decreased if they are not perpendicular to the tear. This could explain the lower healing rate in the posterior zone. Therefore, use of the inside-out technique should be considered for repair of tears in the posterior horn of the medial meniscus.



## CONCLUSION

Previous studies have demonstrated that the location of the tear and the condition of the ACL are important factors in determining the success of meniscal repair. We recommend that patients with concomitant medial meniscus and ACL tears undergo ACL reconstruction combined with meniscal repair. However, because there was a 62% healing rate in patients with an unrepaired ACL tear, consideration should still be given to meniscal repair in patients who refuse ACL reconstruction. Multiple permanent sutures should be used and the patient must be counseled regarding the higher failure rate with this approach. Lateral meniscal repairs have a higher success rate, and consideration should be given to lateral meniscus repair even in the presence of ACL insufficiency. We recommend the use of fibrin clot in isolated meniscal repair, especially for tears in the avascular inner two thirds of the meniscus. Ritchie et al.<sup>7</sup> have shown that abrasion of the parameniscal synovium significantly increased healing of central tears in a goat model. In far-posterior meniscus tears, it may be difficult to start far enough posteriorly, thus resulting in oblique suture orientation across the tear. In this setting, the inside-out technique with a posterior incision may be preferable.<sup>2</sup> We now use MRI for the evaluation of meniscal healing because MRI has been demonstrated to be as accurate as arthrography and MR arthrography for the evaluation of meniscal healing.<sup>19</sup>

## REFERENCES

- Warren RF. Arthroscopic Meniscus Repair. *Arthroscopy* 1985;1:170-172.
- Van Trommel MF, Simonian PT, Potter HG, Wickiewicz TL. Differential healing rates with the outside-in technique for meniscal repair. *Am J Sports Med* 1998;26:446-452.
- Rodeo SA, Warren RF. Meniscal repair using the outside-to-inside technique. *Clin Sports Med* 1996;15:469-481.
- Johnson L. Meniscus repair: The outside-in technique. In: Jackson DW, ed. *Master Techniques in Orthopaedic Surgery: Reconstructive Knee Surgery*. New York: Raven Press; 1995:51-68.
- Barrett GR, Richardson K, Ruff CG, Jones A. The effect of suture type on meniscus repair: A clinical analysis. *Am J Knee Surg* 1997;10:2-9.
- Rimmer MG, Nawana NS, Keene GCR, Percy MJ. Failure strengths of different meniscal suturing techniques. *Arthroscopy* 1995;11:146-150.
- Ritchie JR, Miller MD, Bents RT, Smith DK. Meniscal repair in a goat model: The use of healing adjuncts on central tears and the role of magnetic resonance arthrography in repair evaluation. *Am J Sports Med* 1998;26:278-284.
- Rodeo SA, Warren RF, Arnoczky SP. Meniscal repair using an exogenous fibrin clot. *Techniques in Orthopaedics* 1993;8:113-119.
- Barber FA. Accelerated rehabilitation for meniscus repairs. *Arthroscopy* 1994;10:206-210.
- Barber FA, Click SD. Meniscus repair rehabilitation with concurrent anterior cruciate reconstruction. *Arthroscopy* 1997;13:433-437.
- Shelbourne KD, Patel DV, Adsit WS, Porter DA. Rehabilitation after meniscal repair. *Clin Sports Med* 1996;15:595-612.
- Mariani PP, Santori N, Adriani E, Mastantuono M. Accelerated rehabilitation after arthroscopic meniscal repair: A clinical and magnetic resonance imaging evaluation. *Arthroscopy* 1996;12:680-686.
- Klein L, Player JS, Heiple KG, Bahniuk E, Goldberg VM. Isotopic evidence for resorption of soft tissues and bone in immobilized dogs. *J Bone Joint Surg Am* 1982;64:225-230.
- Klein L, Heiple KG, Torzilli PA, Goldberg VM, Burstein AH. Prevention of ligament and meniscus atrophy by active joint motion in a non-weight bearing model. *J Orthop Res* 1989;7:80-85.
- Anderson DR, Gershuni DH, Nakhostine M, Danzig LA. The effects of non-weight bearing and limited motion on the tensile properties of the meniscus. *Arthroscopy* 1993;9:440-445.
- Dowdy PA, Miniaci A, Arnoczky SP, Fowler PJ, Boughner DR. The effect of cast immobilization on meniscal healing. *Am J Sports Med* 1995;23:721-728.
- Morgan CD, Casscells SW. Arthroscopic meniscus repair: A safe approach to the posterior horns. *Arthroscopy* 1986;2:3-12.
- Nicholas SJ, Rodeo SA, Ghelman B, Buss DD, Warren RF. Arthroscopic meniscal repair using the outside-in technique. Presented at the annual meeting of the American Academy of Orthopaedic Surgeons, Anaheim, California, February 1991.
- Von Trommel MF, Potter HG, Ernberg LA, Simonian PT, Wickiewicz TL. The use of non-contrast magnetic resonance imaging in evaluating meniscal repair: Comparison with conventional arthrography. *Arthroscopy* 1997;14:2-8.

Faint, illegible text in the left column, possibly bleed-through from the reverse side of the page.

Faint, illegible text in the right column, possibly bleed-through from the reverse side of the page.