

Quantifying the Extent of a Type II SLAP Lesion Required to Cause Peel-Back of the Glenoid Labrum—A Cadaveric Study

Aruna Seneviratne, M.D., Kenneth Montgomery, M.D., Babette Bevilacqua, P.A.C.,
and Bashir Zikria, M.D.

Purpose: To quantify the extent of labral disruption required to cause it to peel back when the peel-back test is performed. **Methods:** Ten cadaveric shoulders were prepared by removal of the deltoid and rotator cuff muscles. The glenohumeral joint was concentrically reduced and brought into 90° abduction and maximal external rotation. The peel-back of the labrum was graded 0, 1, or 2. The labrum was sequentially detached from the glenoid in the following order: biceps anchor only, 1 o'clock, 2 o'clock, 11 o'clock, and 3 o'clock positions. After each labral cut, the peel-back test was performed. Labral repair was performed with a single suture anchor placed at the 12:30 o'clock position; labral peel-back was reassessed. **Results:** A progressive increase was noted in peel-back grade with sequential cutting of the labrum posteriorly. However, disruption of the anchor alone did not lead to a positive peel-back sign. Disruption to the 2 o'clock position resulted in a positive peel-back sign overall in 9 of 10 shoulders (5 were grade 1, and 4 were grade 2). No increase was seen in peel-back grade with anterior extension of the labral detachment. Labral repair with a single anchor placed at the 12:30 o'clock position eliminated labral peel-back in 100% of shoulders. **Conclusions:** Detachment of the biceps anchor alone does not cause peel-back. The labrum must be disrupted to at least the 2 o'clock position before overt (grade 2) peel-back is observed. A single suture anchor placed at 12:30 o'clock eliminated peel-back of the labrum. **Clinical Relevance:** Validation of the peel-back test as an important diagnostic tool during shoulder arthroscopy. **Key Words:** SLAP lesion—Peel-back test—Labrum—Shoulder surgery—Shoulder arthroscopy.

Superior labral anterior posterior (SLAP) lesions were first classified into 4 types by Snyder et al.¹ The type II SLAP lesion, as described by Snyder, involves detachment of the biceps anchor, along with the labrum, at an anteroposterior location and is the focus of this study.

From the Department of Orthopaedic Surgery, Lenox Hill Hospital, New York, New York, U.S.A.

Address correspondence and reprint requests to Aruna Seneviratne, M.D., Department of Orthopaedic Surgery, Lenox Hill Hospital, 130 East 77th St, Black Hall, 5th Floor, New York, NY 10021, U.S.A. E-mail: asene@nycsportsdoctor.com

© 2006 by the Arthroscopy Association of North America
0749-8063/06/2211-5296\$32.00/0
doi:10.1016/j.arthro.2006.06.017

NOTE: To access the supplementary tables accompanying this report, visit the November issue of *Arthroscopy* at www.arthroscopyjournal.org

SLAP lesions, at times, can be a diagnostic dilemma. A variety of clinical signs have been described, including the active compression test, the crank test, the compression rotation test, and the pain provocation test.² None of these tests alone has adequate sensitivity or specificity to rule in or out a type II SLAP lesion. Magnetic resonance arthrograms are the most accurate study available, with a single study demonstrating a sensitivity of 89%, a specificity of 91%, and an accuracy of 90% in detecting labral lesions.³ Sensitivity may be poorer in lesions that are dynamically unstable (+peel-back) but are not acute injuries in which fluid separates the labrum from the glenoid.

Arthroscopy is the most accurate method of diagnosing labral lesions. Burkhart and Morgan described use of the peel-back test to aid in the arthroscopic diagnosis of type II SLAP lesions.⁴ The peel-back

phenomenon occurs when the arm is abducted and externally rotated. This causes the biceps tendon force vector to shift from a horizontal to a vertical orientation, producing a torsional force at the base of the biceps, which is transmitted to the posterior labrum. If the labrum is injured, this will result in peeling back of the labrum medially over the glenoid. This is often a subtle finding, and no grading scale has been prepared for the peel-back phenomenon. Furthermore, the extent of the lesion required to cause peel-back of the labrum is unknown.

The hypothesis of this study was that disruption of the biceps anchor alone is sufficient to cause peel-back of the labrum.

METHODS

A total of 14 human cadaveric shoulders were used in this study, of which 10 met the inclusion criteria (intact biceps tendon, no preexisting SLAP lesion, and absence of severe degenerative joint disease [DJD]). Three specimens were excluded because the biceps tendon was not intact. An additional specimen was excluded because it had a preexisting type II SLAP lesion that extended to the 3 o'clock position. None was excluded because of severe DJD. Demographic data were available for 6 of the 10 specimens. Average age was 48.3 years. Four were female and two were male. Grade 3 DJD was noted in 2 specimens.

Fresh frozen shoulder specimens were thawed at room temperature over 24 hours. These shoulders were individually mounted on a standard specimen holder, and the overlying skin was removed. The deltoid, supraspinatus, infraspinatus, and teres minor portions of the rotator cuff were removed, with care taken to avoid damaging the long head of the biceps. The cuff of tissue overlying the bicipital groove was left in place to preserve normal motion and mechanics of the long head of the biceps tendon. The capsule was left intact anteriorly and posteroinferiorly. The subscapularis tendon was left intact. The coracoacromial and coraco-

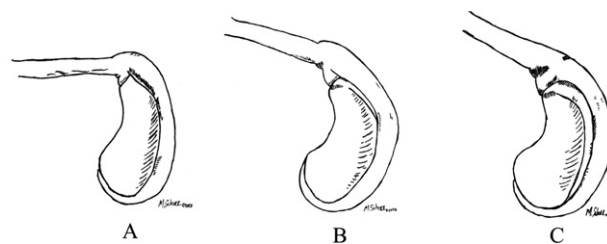


FIGURE 1. Peel-back grading scale viewed from the posterior portal. (A) Grade 0 peel-back. Note the horizontal biceps orientation and complete coverage of the supraglenoid tubercle by the labrum. (B) Grade 1 peel-back. Note the buckling of the biceps root and medialization of the superior labrum, exposing the supraglenoid tubercle. (C) Grade 2 peel-back. The labrum has peeled back medially, fully exposing the supraglenoid tubercle.

humeral ligaments were transected, and the lateral acromion was removed with a saw at the level of the acromioclavicular joint to allow visualization of the biceps anchor complex. In specimens with a short humerus, a Schantz pin was placed distally to mimic the forearm and to improve the mechanical advantage to facilitate movement of the glenohumeral joint.

The glenohumeral joint was concentrically reduced manually and was brought into 90° of abduction in neutral rotation. Concentrically reducing the shoulder involved centering the humeral head on the central portion of the glenoid. This position was maintained with application of an axial manual load to the humerus. The long head of the biceps was manually loaded for application of approximately 4 lb of force.⁵ The humerus was then maximally externally rotated, and the labrum was observed. The peel-back phenomenon was graded as described in Table 1 and Fig 1. The preceding motion was reproduced after each intervention as described here. The labrum was detached from the glenoid with the use of a No. 11 scalpel in the following sequence: biceps anchor only, posteriorly to the 1 o'clock position, posteriorly to the 2 o'clock position, anteriorly to the 11 o'clock position, and posteriorly to the 3 o'clock position (all glenoids were normalized to the left side). The labrum was repaired to the supraglenoid tubercle with placement of a single suture anchor (3.0 mm Bio-Suture-Tak; Arthrex, Naples, FL) at the 12:30 o'clock position. Data were recorded on an Excel worksheet (Microsoft, Redmond, WA). Statistical analysis was performed with a standard statistical package (Statistical Package for the Social Sciences; SPSS Software, Chicago, IL). The Friedman test was used to discern whether a progressive change in peel-back grade occurred with sequential disruption of the labral attach-

TABLE 1. Grading Scale of the Peel-Back Phenomenon

Grade	Description
0	No peel-back of the labrum
1	Medialization of the biceps anchor and initiation of medial labral peel-back without rolling over of the glenoid margin
2	Overt peel-back of the labrum over the posterior superior glenoid

ment. One-tailed Wilcoxon signed ranks tests were used to compare changes in peel-back grade at each level of disruption (intact v anchor disruption only; anchor disruption v 1 o'clock, etc.). Sample size was based on the ability to detect a positive peel-back sign with disruption of the anchor only. Peel-back to at least a grade 1 with disruption of the anchor only could be detected as significant ($P < .05$ at 80% power) if such an effect was evident in 4 of 10 specimens. Statistical significance was set at $P < .05$.

RESULTS

Demographic data were available for 6 of the 10 specimens, which consisted of 4 female and 2 male specimens with an average age of 48.3 years (38 to 57 years). Of the 10 shoulders, 4 were left and 6 were right. Labral morphology was normal in 9 specimens and meniscoid in 1.

Biceps tendon insertion morphology was type II in 5 specimens and type III in 1 specimen, according to the classification of Vangsness et al. (Table 2, online only, available at www.arthroscopyjournal.org).⁶ A progressive increase in peel-back grade was observed with sequential cutting of the labrum posteriorly ($P =$

.0001). However, disruption of the anchor alone did not lead to a positive peel-back test ($P = .32$), with 9 of 10 specimens having a grade 0 peel-back sign, thus validating the null hypothesis of this study (disruption of the biceps anchor alone is not sufficient to cause peel-back of the labrum). A positive peel-back sign was evident in 5 of 10 specimens at 1 o'clock ($P = .046$)—a significant increase when compared with disruption of the anchor alone. In all, 4 of 10 grade 1 and 1 grade 2 peel-backs of the labrum were reported. Disruption to the 2 o'clock position resulted in a positive peel-back sign overall in 9 of 10 specimens (5 grade 1 and 4 grade 2)—a significant increase compared with the 1 o'clock position ($P = .02$). No further increase in peel-back grade was noted with anterior extension of the labral detachment ($P = .317$). Only 1 specimen converted from grade 1 to grade 2 (Table 3, online only, and Fig 2). No statistically significant increase occurred in the proportion of occurrences of grade 2 peel-back at the 3 o'clock level compared with the 2 o'clock level ($P = .157$).

The single specimen that remained with a grade 0 peel-back demonstrated a meniscoid labrum. This specimen was not subject to repair because no peel-back of the labrum had occurred.

Peel Back Percentages

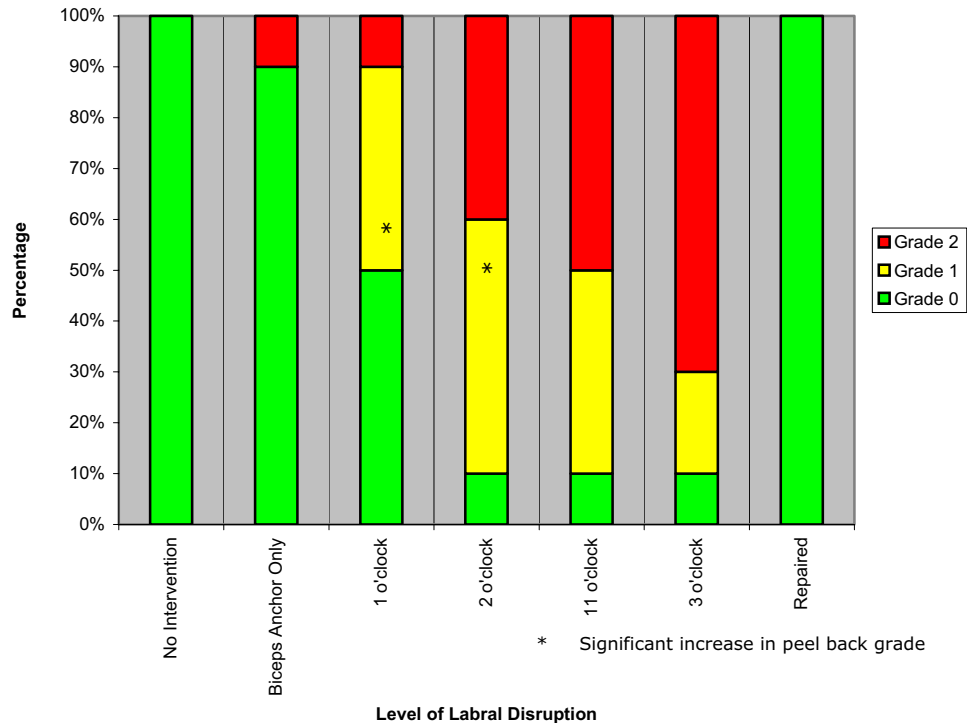


FIGURE 2. Peel-back percentages. A progressive increase in peel-back grade was seen with sequential cutting of the labrum posteriorly. Disruption of the anchor alone did not lead to a positive peel-back sign. Disruption to the 2 o'clock position resulted in a positive peel-back sign in 90% of the specimen. Repair of the labrum with a single anchor at the 12:30 o'clock position eliminated the peel-back sign in 100% of the specimen.

Repair of labral disruption with a single anchor placed just posterior to the biceps anchor at the 12:30 o'clock position eliminated the peel-back sign in 9 of 9 (100%) specimens that were repaired. Thus, restoration of the peel-back sign to grade 0 was evident with repair in all specimens ($P = .005$) when compared with the group with labral disruption to the 3 o'clock position before the time of repair. After repair, the labral tissue at the 2 and 3 o'clock positions remained well coapted to the glenoid in internal rotation of the humerus, but not when the humerus was in external rotation.

DISCUSSION

Type II SLAP lesions were originally believed to occur as a result of acute trauma. This could take the form of a compression/sheer mechanism, as in the case of a fall on the outstretched arm, or could occur as traction injury, as in the case of deceleration of the arm after a throw, as described by Andrews et al.⁷ Burkhart et al.^{4,8,9} has suggested an alternative mechanism that results from chronic attritional disruption of the biceps anchor due to repetitive stress during throwing. They observed these injuries to occur in the late cocking phase and described the peel-back phenomenon as the principal pathophysiologic pathway in which the biceps tendon force vector shifts from an anterior-horizontal direction to a more vertical and posterior direction. This produces torsional force at the base of the biceps that is transmitted to the posterior labrum. Such a torsional force tends to peel back the labrum. Repetitive traction, particularly with posterior superior migration of the humeral head, results in progressive attrition of anchor fibers and subsequent dynamic instability. Recent biomechanical evidence supports the peel-back phenomenon as the predominant causative mechanism in type II SLAP lesions.¹⁰

This study demonstrates that disruption of the biceps anchor alone is insufficient to cause the labrum to peel back over the glenoid rim, thus proving the null hypothesis. Data support the observation that visualization of a grade 2 peel-back sign implies likely labral disruption to the 2 o'clock position. Anterior extension of the labral disruption did not contribute significantly to an increase in the peel-back grade. A single suture anchor placed just posterior to the biceps anchor at the 12:30 o'clock position eliminated the peel-back phenomenon in all shoulders, thus further validating the observations of Burkhart et al.⁴

Vangsnæs et al.⁶ have described 4 variants of the biceps tendon attachment to the glenoid and labrum. Only 1 specimen was observed to have a type III attachment (equal contribution of the biceps to the anterior labrum and the posterior labrum). This specimen failed to demonstrate grade 2 peel-back, even at the 3 o'clock position of labral disruption. It is interesting to note that the opposite shoulder from the same subject demonstrated a type II biceps attachment (with most fibers attaching to the posterior labrum and a small contribution to the anterior labrum) and failed to demonstrate a grade 2 peel-back. Initially, it was thought that peel-back of the labrum did not occur in meniscoid specimens or biceps insertions that were anterior dominant. It is difficult to draw definitive conclusions, given the small number of meniscoid specimens.

Limitations of this study include the small sample size; no anterior dominant biceps insertion shoulders were included in this population. The cutting sequence did not involve cutting anteriorly first. This study required the resection of several key structures surrounding the shoulder, such as the rotator cuff (subscapularis was intact), the posterosuperior capsule, the coracohumeral ligament, and the coracoacromial ligament, to allow visualization of the labrum. This could have altered the anatomic forces that act on the superior labrum during abduction and external rotation. Arthroscopic evaluation of the peel-back phenomenon would have been ideal, but it was not feasible to disrupt the labrum in a systematic, controlled, and sequential manner.

This study supports the importance of performing the peel-back test during the diagnostic portion of shoulder arthroscopy. If grade 2 peel-back occurs, labral disruption to at least the 2 o'clock position is implied. It is important to recognize that if the major stabilizing fibers are inadequate, peel-back may occur, despite the presence of soft tissue attachments, thus leading to a potentially normal finding on magnetic resonance imaging. It has been our clinical experience that magnetic resonance imaging and arthrography have poor sensitivity in detecting dynamic superior labral instability.

The implication for repair of type II SLAP lesions is that a single suture anchor placed just posterior to the biceps anchor at the 12:30 o'clock position will neutralize the posterior force vector and eliminate the peel-back phenomenon. However, from a biological standpoint, it is important to assess appropriate coaptation of the labrum to the glenoid and to use additional anchors as needed. Our cadaveric findings

would suggest that early postoperative rehabilitation of these injuries should limit excessive abduction and external rotation.

In summary, this study demonstrates the extent of a type II SLAP lesion required to cause peel-back of the labrum. The grading scale proposed in this study may enable a more accurate evaluation of the peel-back phenomenon. Clinical validation of the grading scale is planned in a future study.

Acknowledgment: The authors thank Arthrex for providing the suture anchors used for labral repair, and Malachy McHugh, PhD, for assisting with the statistical analysis.

REFERENCES

1. Snyder SJ, Karzel RP, Del Pizzo W, Ferkel RD, Friedman MJ. SLAP lesions of the shoulder. *Arthroscopy* 1990;6:274-279.
2. Tennent TD, Beach WR, Meyers JF. A review of the special tests associated with shoulder examination. Part II: Laxity, instability, and superior labral anterior and posterior (SLAP) lesions. *Am J Sports Med* 2003;31:301-307.
3. Bencardino JT, Beltran J, Rosenberg ZS, et al. Superior labrum anterior-posterior lesions: Diagnosis with MR arthrography of the shoulder. *Radiology* 2000;214:267-271.
4. Burkhart SS, Morgan CD. The peel-back mechanism: Its role in producing and extending posterior type II SLAP lesions and its effect on SLAP repair rehabilitation. *Arthroscopy* 1998;14:637-640.
5. Pradhan RL, Itoi E, Kido T, Hatakeyama Y, Urayama M, Sato K. Effects of biceps loading and arm rotation on the superior labrum in the cadaveric shoulder. *Tohoku J Exp Med* 2000;190:261-269.
6. Vangsness CT Jr, Jorgenson SS, Watson T, Johnson DL. The origin of the long head of the biceps from the scapula and glenoid labrum: An anatomical study of 100 shoulders. *J Bone Joint Surg Br* 1994;76:951-954.
7. Andrews JR, Carson WG Jr, McLeod WD. Glenoid labrum tears related to the long head of the biceps. *Am J Sports Med* 1985;13:337-341.
8. Morgan CD, Burkhart SS, Palmeri M, Gillespie M. Type II SLAP lesions: Three subtypes and their relationships to superior instability and rotator cuff tears. *Arthroscopy* 1998;14:553-565.
9. Burkhart SS, Morgan CD, Kibler WB. The disabled throwing shoulder: Spectrum of pathology. Part I: Pathoanatomy and biomechanics. *Arthroscopy* 2003;19:404-420.
10. Kuhn JE, Lindholm SR, Huston LJ, Soslowky LJ, Blasler RB. Failure of the biceps superior labral complex: A cadaveric biomechanical investigation comparing the late cocking and early deceleration positions of throwing. *Arthroscopy* 2003;19:373-379.

